

Onychodystrophy On Twenty Nails Caused By *Candida Parapsilosis* and *Staphylococcus Aureus*: A Case Report

Ariani, T.¹, Putri, H.A.²

¹ Head of Infection Division, Dermatovenereologist, Dept of Dermatology Venereology Medical Faculty of Andalas University, Dr. M. Djamil Hospital, Padang, West Sumatera, Indonesia

E-mail :tutty_masri@yahoo.com

² Resident, Dept of Dermatology Venereology Medical Faculty of Andalas University, Dr. M. Djamil Hospital, Padang, West Sumatera, Indonesia

Abstract

Introduction: Onychodystrophy can caused by variety of underlying diseases such as fungal and nonfungal infections, various noninfectious inflammatory dermatologic diseases of the nail unit and tumors. To establish the underlying disease leading to nail dystrophy as a first step one should differentiate between infectious and noninfectious disorders by obtaining nail material for microscopic examination and culture. **Case Report:** A case of onychodystrophy on twenty nail in 43 years old housewife woman was reported. The chief complaint was all of her fingernails and toenails were brittle, the color became yellow brown blackish since 6 month ago and sometimes excreted smell discharge. There were onychodystrophy, onycholysis, subungual hyperkeratosis and yellow brown blackish discolorization of all fingernails and toenail on physical examination. There were longitudinal striae, aurora borealis pattern, jagged margin of proximal edge on dermoscopic examination. Microscopic examination of nail clipping and scrapping of fingernails with 20 % potassium hydroxide was negative. The culture of fungi showed *Candida Parapsilosis*. Culture of bacteria was *Staphylococcus aureus*. PAS stain from nail clipping resulted was *Candida Spp*. Patient treated with oral pulse antifungal itraconazole 2x200 mg/day combination with ciprofloxacin 2x500 mg twice a day and ketokonazol cream twice a day. **Conclusion:** Onychodystrophy can caused by onychomycosis aggravated by bacterial infection. Diagnosis of onychomycosis candida was made base on diagnosis, physical examination, microscopic, culture and histopatology. Predisposition factor in this patient was chronic exposure with water. There is improvement clinical appearance after therapy with antifungal and antibiotic

Key words - Onychodystrophy, Candida Onychomycosis, Trachyonychia, Onychoscopy, Nail PAS Stain

Abstrak

Pendahuluan: Onikodistrofi dapat disebabkan oleh berbagai penyakit yang mendasari seperti infeksi fungi dan non fungi, berbagai penyakit noninfeksius pada unit kuku dan tumor. Untuk menetapkan penyakit yang mendasari yang mengarah ke distrofi kuku sebagai langkah pertama adalah membedakan infeksius atau non infeksius dengan pemeriksaan kuku dan kultur. **Laporan Kasus:** Sebuah kasus onikodistrofi pada semua kuku jari tangan dan kuku kaki pada wanita rumah tangga berusia 43 tahun. Keluhan utama adalah semua kuku tangan dan kakinya rapuh, warnanya menjadi kuning kecoklatan sejak 6 bulan lalu dan terkadang mengeluarkan bau busuk. Pasien sudah diterapi oleh dokter kulit dengan flukonazol 150 mg / minggu dan krim mikonazol 2xsehari selama 4 bulan namun belum ada perbaikan Pemeriksaan fisik onikodistrofi, onikolisis, hiperkeratosis subungual dan perubahan warna kuning kecoklatan pada kuku. Pemeriksaan mikroskopis kerokan kuku dengan kalium hidrosida 20% negatif. Kultur jamur menunjukkan *Candida spp*. Kultur bakteri menunjukkan *Staphylococcus aureus*. Pewarnaan PAS menunjukkan *Candida Spp*. Pasien diobati dengan Citrakonazole oral 2x200 mg / hari dikombinasi dengan ciprofloxacin 2x 500mg sehari dan krim ketokonazol dua kali sehari. **Kesimpulan:** Onikodistrofi dapat disebabkan oleh onikomikosis disertai infeksi bakteri. Diagnosis onikomikosis candida dibuat berdasarkan diagnosis, pemeriksaan fisik, mikroskopis dan kultur. Faktor predisposisi pasien ini adalah paparan kronis dengan air. Terdapat perbaikan setelah pemberian terapi itraconazole 400 mg / hari pulse dose, ciprofloxacin 2x 500mg dan krim ketokonazol dua kali sehari.

Katakunci — Onikodistrofi, Onikomikosis Kandida, Trakonikia, Onikoskopi, Pewarnaan PAS

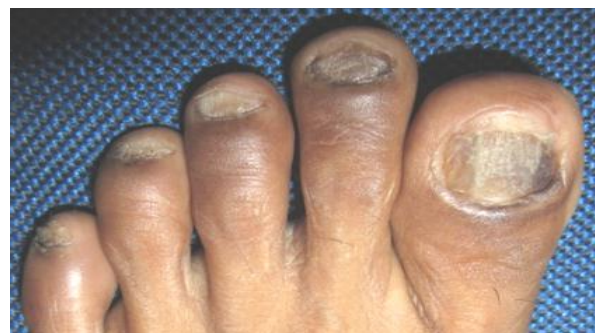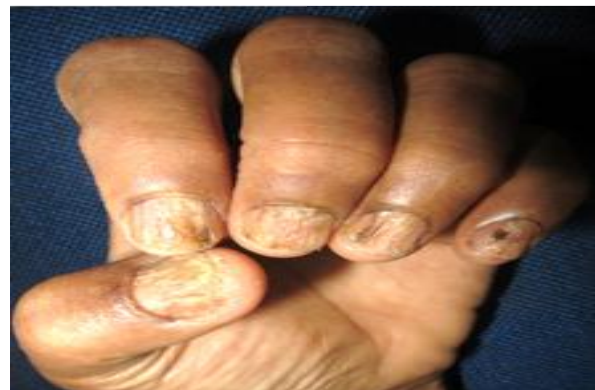I. Introduction

Onychodystrophy is malformation of the nail. Onychodystrophy can be caused by variety of underlying diseases such as fungal and nonfungal infections, various noninfectious inflammatory dermatologic diseases of the nail unit and tumors. Twenty-nails dystrophy or trachyonychia is widespread dystrophy involving all twenty nails, can be idiopathic or is caused by many conditions such as lichen planus, eczema, psoriasis and alopecia areata. Onychomycosis though can lead to total dystrophic onychomycosis, but is not considered as a cause of twenty-nails dystrophy.^{1,2,3} *Candida* onychomycosis is onychomycosis caused by *candida spp.* *Candida albicans* and *C. parapsilosis* are most commonly isolated yeasts from abnormal toe nails but *C parapsilosis* is the most prevalent of the two. The role of the *Candida* species in the pathogenesis of nail disease is complex. *Candida* infection of the nails and paronychia folds occur most often in diabetes mellitus patients or who have frequently contact of their hands with water (i.e., housekeepers, bakers, fishermen, and bartenders). However, a secondary bacterial infection can be present.^{1,4}

II. CASE REPORT

A 43-year-old woman came to the outpatient of Dermato-Venereology Departement of Dr. M. Djamil Padang with chief complaint her twenty nails were thickened, ridging, the color became yellow-brown blackish since 6 month ago. There was history of skin around the finger felt itchy, had reddish patches and secreted smell bad fluid. She is a house wife and doing all the dishes and wash the clothes in the sink. Her hands and feets frequently contactede was withwater. There were no itchy red patches on other parts of the body. History of HIV, malignancy, diabetes mellitus or other immunocompromised conditions was denied. Physical examination results on all of fingernails and toenails

showed onychodystrophy, onycholysis, yellow brown blackish discoloration, longitudinal line and hyperkeratosis subungual. Dermoscopic examination revealed jagged margin at proximal edge, aurora borealis pattern and longitudinal striae. Microscopic examination of nail clipping and scrapping of fingernails with 20 % potassium hydroxide was negative. The culture of fungi showed *Candida Parapsilosis*. Culture of bacteria was *Staphylococcus aureus*. PAS stain from nail clipping revealed budding yeast (blastospora) interpreting a *Candida Spp* colony. Patient treated with oral pulse antifungal Itraconazole 2x200 mg/day combination with Ciprofloxacin 2x500 mg twice a day according to the sensitivity results and ketokonazol cream occlusive on all of nails twice a day.



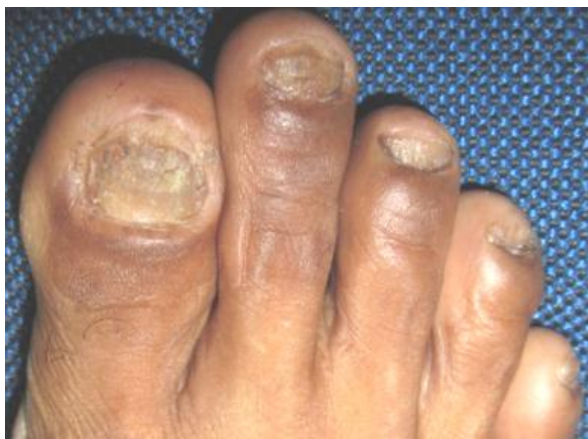

FIGURE 1. ONYCHODYSTROPHY, ONYCHOLYSIS, GREEN-BROWN-BLACKISH DISCOLORATION, LONGITUDINAL LINE WERE POSITIVE, HYPERKERATOSIS SUBUNGUAL ON ALL OVER THE NAIL.

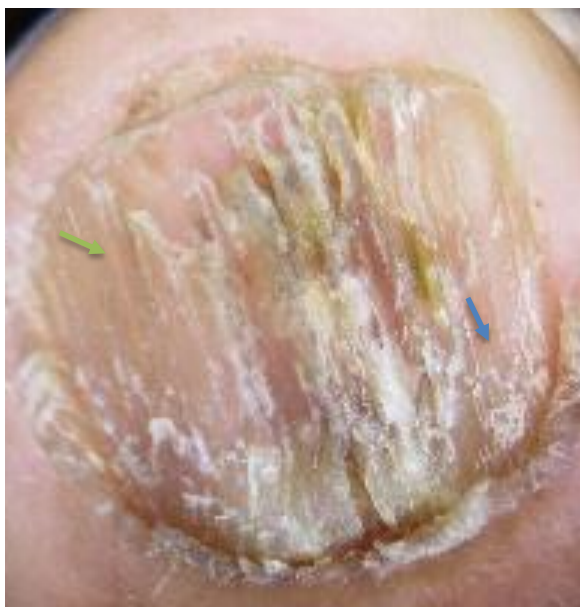

FIGURE 2. DERMOSCOPIC FINDING FROM DIGITI 1 RIGHT HAND A. JAGGED MARGIN AT PROXIMAL EDGE (BLUE ARROW), CIRCLE), LONGITUDINAL STRIAE (GREEN ARROW)

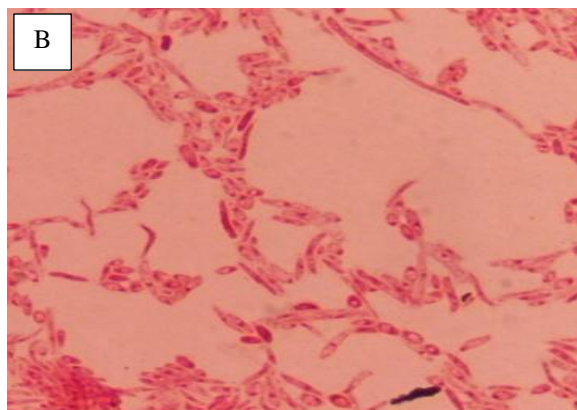


FIGURE 3. NAIL CULTURE ON SABORAUD DEXTROSE AGAR (A) CREAMY WITH LACY APPEARANCE DUE TO CANDIDA PARAPSILOSIS (B) CANDIDA PARAPSILOSIS ON GRAM STAIN

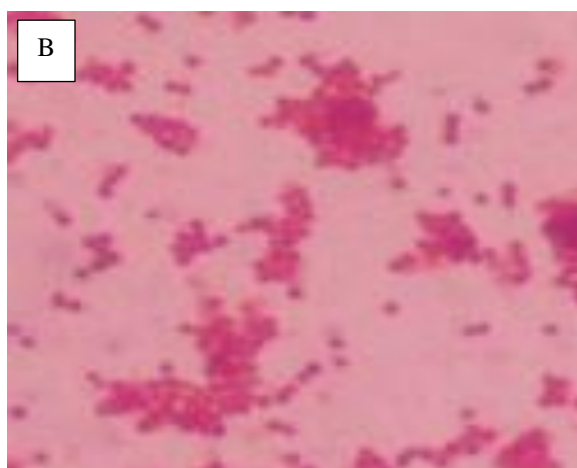
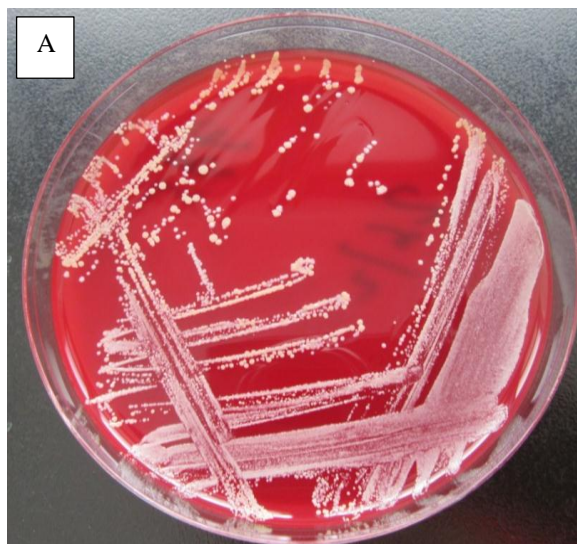


FIGURE 4. NAIL CULTURE ON BLOOD AGAR PLATE (A) WHITE YELLOWISH COLONIES (B) COCCI ARE ARRANGED IN CLUSTERS RESEMBLING GRAPE STRANDS ON GRAM STAIN

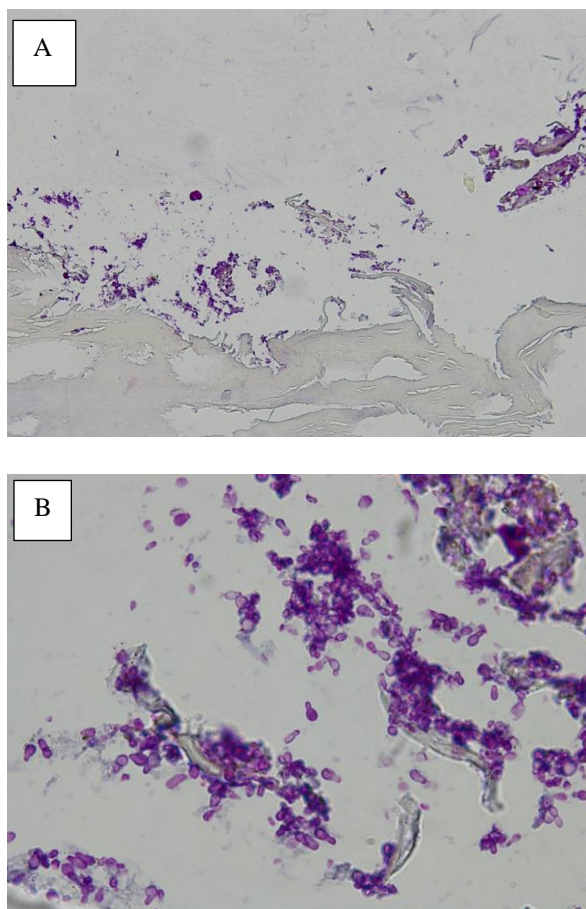


FIGURE 5. HISTOPATHOLOGICAL FINDINGS OF NAIL CLIPPING PAS STAIN (A) CANDIDA SPP COLONY (RED CIRCLE), NAIL PLATE (BLUE ARROW) (OBJ10X) (B) BLASTOSPORA (OBJ.100X)

III. DISCUSSION

We reported a housewife woman with candida onychomycosis. The patient did all activity including wash the dishes and clothes and frequently keeping the hands and feet moist and immersed in water.

Several studies mentioned the incidence of candidiasis onychomycosis was more often in woman than man. Narain U et al. observed a male-to-female ratio of onychomycosis was 33.80: 66.20. Bokhari et al. observed 72% of female patients in their study suffered from onychomycosis while Elewski and Cohen et al showed a male preponderance and gender included as a general risk factor for onychomycosis. Candida onychomycosis is the most common type of infection associated with

fingernails of female. CHousewives (52.6%) and chefs (10.5%) were the most common occupational risk factor as reported in previous studies, probably due to its chronic exposure to water.⁴ Trachyonychia (twenty-nails dystrophy) is a nail sign that can be caused by several inflammatory disorders that produce a mild disturbance of nail matrix keratinization. These include alopecia areata, psoriasis, lichen planus and eczema.^{1,2} On anamnesis and physical examination, there were no abnormality of her hair, no itchy and reddish patches with white thickened scales on another parts of the body, and no pitting and salmon patches on her nails. Furthermore, sign of hand dermatitis was not found. Lichen planus nail often affects both the nail matrix and the nail bed. Clinical suspicion should be aroused by nail matrix signs, particularly nail thinning with longitudinal ridging, fissuring, and pterygium formation.^{1,2}.

Twenty nails dystrophy can be diagnosis if the infection of nail was excluded. A microscopic examination of nail clipping and scaling of 20% potassium hydroxide was performed and the results showed no hyphae or pseudohyphae was observed. A culture examination was performed twice and the resulted revealed *Candida spp*. A research about incidence of onychomycosis January 2013 - July 2016 in dermatology and venereology Dr. M. Djamil Padang was done by Gaya et al. The results showed the most common causative organisms were *Candida spp* (57%), *Aspergillus spp* (11%), *Trychophyton Rubrum* (9%), unidentified (1.9%).⁵ Due to both culture results were negative for dermatophyte, a nail clipping histopathologist analysis was planned to be done.

Histopathological examination with Periodic Acid Schiff (PAS) staining showed budding yeast (blastospora), proven *Candida spp*. Histological analysis with PAS was found to be more sensitive than KOH preparation or culture alone (92% versus 80% or 59%).

PAS staining plus culture had the best sensitivity overall. The finding of hyphae or spora in nail plate may differ from psoriasis, lichen planus and other causes of nail dystrophy.²

Furthermore, a bacterial culture was performed to find out concomitant bacterial infection. The bacterial culture from nail was *Staphylococcus aureus* and treated with Ciprofloxacin 2x500mg according to the results of culture and sensitivity test. Elewski BE reported pseudomonas infection in a patient with onychomycosis, after four weeks therapy with ciprofloxacin 2x500mg, the bacterial culture was negative.⁶

Onychomycosis can be divided into cases with and without matrix area involvement. In cases without matrix area involvement, topical treatment alone can be sufficient for treatment, whereas oral and combination treatments are recommended for cases with matrix involvement.¹ We administered systemic of three pulse itraconazole 400 mg per day for a week with 3 week off without medication. Before administered itraconazole, liver function test was performed and planned to check month because itraconazole could disturb liver function. On this patient there was mixed infection of fungi and bacteria so it must be treated bacterial infection due to *Staphylococcus aureus* and we treated with Ciprofloxacin 2x500mg based on sensitivity test.

IV. CASE REPORT WEAKNESS

Non-adherence patient to the control schedule led to incomplete data regarding the continuation of follow-up and inadequate therapy.

V. CONCLUSION

Onychodystrophy can be caused by onychomycosis aggravated by bacterial infection. Diagnosis of onychomycosis candida was made based on diagnosis, physical examination, microscopic, culture and histopathological examination. Complete examination is needed so that it can be treated appropriately.

REFERENCES

- [1] Schieke SM, Garg A. Superficial fungal infection. In: Wolff K, Goldsmith LA, Katz SI, Gilchrest BA, Paller AS, Leffel DJ, editors. Fitzpatrick Dermatology in general medicine. Eighth edition, volume two. New York: McGraw Hill; 2012: 2277-97.
- [2] Sobera JO, Elewski BE. Onychomycosis. In: Nails Diagnosis Therapy Surgery, Scher RK, Daniel III CR. Third Edition, USA; 2005:123-130
- [3] Oppel T, Korting HC. Onychodystrophy and its management. German Medical Science ;2003:1-7
- [4] Narain U, Bajaj AK. Candida onychomycosis: Indian scenario. International Journal of Advanced Medicine. 2016 Aug;3(3):638-642
- [5] Gaya ML et al. A retrospective study of onychomycosis in dermatology and venereology outpatient clinic of Dr.M.Djamil Hospital Padang (January 2013-July 2016). In: Programme and abstract the 6th asia pacific society for medical mycology congress. Bali;2016:130
- [6] Elewski BE. Pseudomonas infection in a patient with onychomycosis. Journal of American Academy of Dermatology.1997;493-494
- [7] Gupta AK, Daniel CR. Factors that may affect the response of onychomycosis to oral antifungal therapy. Australasian Journal of Dermatology. 1998; 222-224
- [8] Grover C, Jakhar D. Diagnostic utility of onychoscopy review of literature. Indian Journal of Dermatopathology and Diagnostic Dermatology.2017;31-40
- [9] Piraccini BM, Balestri R, Starace M, Rech G. Nail digital dermoscopy (Onychoscopy) in the diagnosis of onychomycosis; Journal of the European Academy of Dermatology and Venereology ; 2011:1-5

- [10] Arca E et al. An open, randomized, comparative study of oral flukonazole, itraconazole and terbinafine therapy in onychomycosis. *Journal of Dermatological Treatment*;2002;13:3-9
- [11] Brown SJ. Efficacy of flukonazole for the treatment of onychomycosis. *The annals of pharmacotherapy*;2009:1684-1691